

The Effects of an Interspinous Implant on Intervertebral Disc Pressures

Kyle E. Swanson, MD* Derek P. Lindsey, MS,† Ken Y. Hsu, MD,‡
James F. Zucherman, MD,‡ and Scott A. Yerby, PhD*†§

Study Design. Measurement of intradiscal pressure was performed after placement of an interspinous implant in a cadaver model.

Objective. To understand the likelihood of accelerated adjacent-level disc degeneration as a result of the implant.

Summary of Background Data. An interspinous implant has been developed to treat lumbar neurogenic claudication secondary to spinal stenosis that places the stenotic segment in slight flexion and prevents extension. Previous biomechanical studies demonstrated that fusing one level may significantly increase the intradiscal pressures at adjacent levels. Moreover, clinical studies have reported an increased incidence of adjacent-level degeneration after lumbar spinal fusion.

Methods. Eight cadaver lumbar specimens (L2–L5) were loaded in flexion, neutral, and extension. A pressure transducer measured intradiscal pressure and annular stresses during each of the three positions at each of the three disc levels. An appropriately sized implant was placed at L3–L4, and the pressure measurements were repeated.

Results. The pressures at the adjacent discs were not significantly affected by the interspinous implant insertion. There was a significant decrease in intradiscal pressure at the L3–L4 disc in the posterior annulus and nucleus in the neutral and extended positions.

Conclusions. The implant does not significantly change the intradiscal pressures at the adjacent levels, yet it significantly unloads the intervertebral disc at the instrumented level in the neutral and extended positions. On the basis of the current findings, it does not appear that the implant causes accelerated disc degeneration at the adjacent levels. [Key words: disc pressure, interspinous implant, neurogenic intermittent claudication, spinal stenosis] **Spine 2003;28:26–32**

Lumbar neurogenic claudication secondary to spinal stenosis is a disabling condition that causes lower back pain and lower extremity pain resulting from narrowing of the spinal canal.^{9,21,40,46,53–55} Degenerative lumbar spinal stenosis is the most common type, with a reported incidence of 1.7% to 8% of the general population.²³ Most of these patients initially present in the fifth or sixth decade of life with lower back or lower extremity pain. The pathogenesis of degenerative lumbar stenosis begins with degeneration of the posterolateral annulus, advancing to disc herniation and resorption, then to instability with loss of disc height, and finally to stenosis from hypertrophy of the facet joints.^{5,27} Loss of disc height may also cause thickening or “buckling” of the ligamentum flavum at the affected level, contributing to narrowing of the spinal canal.^{11,18,41}

Verbiest⁵³ first described neurogenic intermittent claudication and attributed the pathology to narrowing of the spinal canal and posture. Neurogenic claudication is characterized by one or more of the following symptoms: pain, paresthesias, or decreased sensation and motor power in the legs during walking or standing with relief of symptoms during resting and sitting.^{40,53} While the patient is walking, he or she gradually bends forward to relieve symptoms, ultimately needing to stop for complete relief.⁴⁰ These symptoms are observed mostly because narrowing of the neural foramen results in impingement of the exiting nerve root.^{17,53} Other factors may include radicular ischemia and soft tissue impingement.⁴⁰ Lumbar extension, as seen with standing or walking, exacerbates symptoms by decreasing the foraminal width, height, and area at the exiting nerve root, whereas flexion, as seen with sitting, causes improvement of symptoms by increasing the cross-sectional area of the foramen.^{17,24,38,45,49,50,56,59,62}

Currently, patients with symptomatic lumbar stenosis have treatment options that range from conservative (nonsteroidal antiinflammatory drugs [NSAIDs], physical therapy, epidural steroid injection, and bracing) to surgical (decompressive laminectomy with or without fusion and instrumentation).²³ Several studies have shown that operative treatment gives better results for relief of symptoms, but there are associated risks, especially in older patients.^{22,25,42} It has been estimated that by 2025, the population older than 65 years will have almost doubled.⁴² Less morbid surgical options will need to be developed for those considered nonsurgical patients who have failed conservative treatment.

From the *San Francisco Orthopaedic Residency Program, San Francisco, California, the †VA Rehab R&D Center, Palo Alto, California, the ‡St. Mary's Spine Center, San Francisco, California, and the §St. Francis Medical Technology, Concord, California.

Acknowledgment date: August 24, 2001. First revision date: March 12, 2002. Second revision date: April 23, 2002.

Acceptance date: May 20, 2002.

Device status/drug statement: The devices and drugs that are the subject of this manuscript are being evaluated as part of an ongoing FDA-approved investigational protocol (IDE) or corresponding national protocol to treat intermittent neurogenic claudication secondary to spinal stenosis in the lumbar spine. The devices and drugs that are the subject of this manuscript are not FDA approved for this indication and are not commercially available in the United States.

Conflict of interest: Corporate and industry funds were received in support of this work. One or more of the authors have received or will receive benefits (e.g., royalties, stocks, stock options, decision-making position) for personal or professional use from a commercial party related directly or indirectly to the subject of this article.

Address reprint requests to Scott A. Yerby, PhD, St. Francis Medical Technologies, 1900 Bates Avenue, Suite L, Concord, CA 94520. E-mail: scotty@sfmt.com.

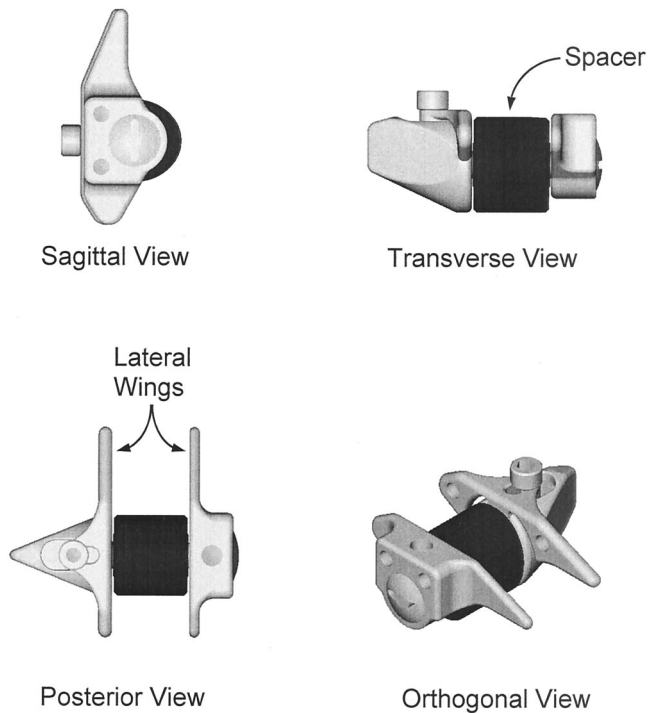


Figure 1. A schematic of the X-Stop implant in three planar views and an orthogonal view. The spacer rests between the spinous processes, and the lateral wings rest lateral to the spinous processes.

A newly developed spinal implant has been designed to treat symptomatic lumbar stenosis, especially in patients with neurogenic claudication who obtain nearly complete relief in sitting or flexing. The device is composed of an oval spacer made of titanium placed between two adjacent lumbar spinous processes (Figure 1). There are two lateral wings on each end of the implant that keep it in place and prevent the implant from migrating laterally. Surgical implantation is performed with the patient under local anesthesia in the lateral decubitus position. The procedure requires muscular stripping of only the paraspinal muscles attached to the spinous processes and not the laminae, and does not require removal or transection of any midline structures. The implant is placed in the interspinous space with the patient in a slightly flexed position. The intent is to position the stenotic segment in slight flexion, and by preventing extension, to relieve the symptoms of lumbar spinal stenosis.

The intent of the current study was to understand changes in intradiscal pressure that occur after placement of the implant. A study by Adams et al³ measured pressures in the intervertebral disc after applying physiologic loads. They observed that the pressures in the posterior annulus increased with extension and decreased with flexion in discs that were not degenerative. When the discs were subjected to degenerative treatment, there was a paradoxical decrease in posterior annular pressure during extension in most specimens. This was explained by possible stress shielding of the posterior annulus by the zygapophysial joints. Another study by

Cunningham et al¹² reported the changes in intervertebral disc pressures after destabilization of the lumbar spine followed by stabilization with instrumentation. Stabilization with posterior instrumentation resulted in a significant increase in pressure at the adjacent levels. Conversely, others have shown little change in disc pressure with lumbar instrumentation.^{10,43,44} There is strong evidence based on clinical and biomechanical findings that increased disc pressure leads to disc degeneration.^{12,16,20,30,48,57} A possible concern with the current implant is how the implant affects the disc pressures at the adjacent levels of insertion and at the level of insertion. The authors hypothesized that placement of an interspinous implant would cause a decrease in the intervertebral disc pressure at the level of instrumentation without significantly affecting the disc pressures at the adjacent levels.

■ Materials and Methods

Eight cadaver lumbar spines were obtained from donors ages 56 to 80 years and stored at -22 C. The specimens were thawed and separated into motion segments consisting of four vertebrae (L2–L5) and three corresponding vertebral discs. Each specimen was debrided of muscle and adipose tissue with the ligamentous structures left intact. Polymethylmethacrylate (PMMA) was used to secure L2 and L5 endplates. The specimens were then placed in a freezer and stored at -22 C until they were needed for testing.

At the time of the experiment, the specimens were thawed to room temp (22 C) and loaded onto a computer-controlled hydraulic materials testing machine capable of applying independent axial loads and bending moments (MTS 858, Eden Prairie, MN).

The specimens were wrapped in a polyethylene sheet to keep them hydrated during the experiment.² Before testing, with the spines placed in the neutral position, a compressive force of 300 N was applied to each specimen for 15 minutes. This technique was performed to precondition the specimens and reduce any postmortem superhydration effects of the intervertebral discs.^{2–4} This was done once for each specimen.

A pressure transducer with a diameter of 1.3 mm (Gaeltec, Hackensack, NJ) was placed into the appropriate disc level with the tip just through the posterior annulus to allow for stress profilometry of the respective disc. A linear variable displacement transducer (LVDT; Sensotec, Columbus, OH) was used to measure the position of the pressure transducer as it was drawn through the disc. Both of the transducers were located on the same apparatus, allowing for simultaneous measurements of pressure and displacement (Figure 2). Initially, each motion segment was placed in the loading frame in the neutral position and subjected to an axial force of 700 N for 30 seconds, at which time the pressure transducer was pulled along the midsagittal plane of the disc being measured. A 700-N force was chosen because it is approximately the amount of force observed in the lumbar spine during sitting and has been used in similar *in vitro* disc pressure studies.^{2,35} Both superior and lateral components of the compressive stress were measured by rotating the transducer needle 90° during successive tests.⁴ Stress profilometry was performed for each disc (L2–L5) with the specimens in neutral, flexed, and extended positions. Flexion and extension were achieved by applying a

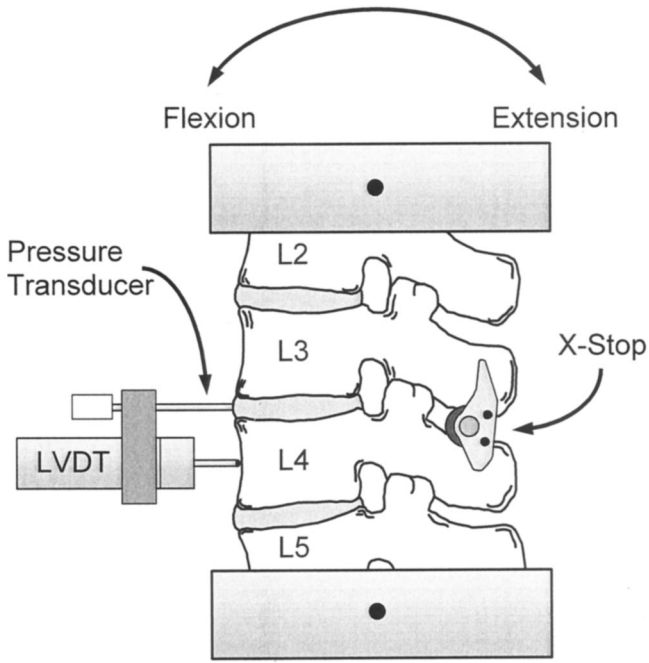


Figure 2. A schematic of the testing configuration. Spines were flexed, extended, and held in the neutral position while a pressure transducer was pulled through the disc from posterior to anterior and the linear variable displacement transducer (LVDT) simultaneously recorded the displacement of the pressure transducer.

7.5-Nm bending moment in the respective direction with a superimposed 700-N compressive load.

Next, an implant (X-Stop; St Francis Medical Technologies, Concord, CA) was placed between the L3 and L4 spinous processes. The size of the X-Stop used was dictated by the size of each individual specimen. The device was placed between the spinous processes of L3 and L4 by creating a rent through the interspinous ligament with a sharp scalpel and then dilating it to the appropriate size. After placement of the implant, the specimen was placed once again in the loading frame. The aforementioned sequence was repeated with the specimens loaded in the neutral, flexed, and extended positions. A 700-N compressive load was used in each position, and a 7.5-Nm bending moment was used to create flexion or extension. Again, a transducer was used to measure the intradiscal pressure during loading, and a displacement transducer was used to measure the travel of the pressure transducer through the disc.

A total of 12 measurements were recorded for each disc level (6 without and 6 with the X-stop). The mean pressures were compared between the intact and implanted specimens for a given level (L2–L3, L3–L4, L4–L5), specimen position (flexion, neutral, extension), transducer direction (superior, lateral), and disc region (posterior, nucleus, anterior). A total of 54 comparisons were made using individual paired *t* tests, each with 0.05 regarded as the level of significance.

■ Results

As expected, the most notable differences in mean disc pressure were identified at L3–L4 (Figure 3). In extension, the mean pressure in the posterior annulus was significantly reduced with the use of the implant (Figure 4, Table 1): the mean superior pressure by 63% and the mean lateral pressure by 46%. Likewise, the mean pres-

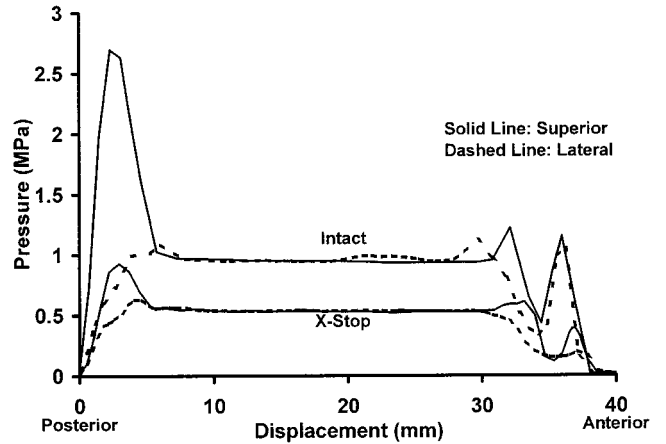


Figure 3. A representative plot of data collected at L3–L4 in extension with and without the X-Stop implant. The plot shows that the implant reduces the pressure in the posterior annulus and nucleus. Also, for a given specimen configuration (intact or X-Stop), the pressure in the nucleus does not change relative to the direction of the pressure transducer, whereas it does change in the anterior and posterior annulus. This indicates that the loading environment in the nucleus is that of hydrostatic compression, whereas the annular walls are loaded in a mixed mode.

ures in the region of the nucleus were significantly reduced after implantation (Figure 4, Table 1): the mean superior pressure by 41% and the mean lateral pressure by 40%. In the neutral position, the mean pressures in the posterior annulus and nucleus were also significantly reduced by the implant (Figure 5, Table 1): the mean superior pressure in the posterior annulus by 38% and the mean superior and lateral pressures in the nucleus by 20% and 17%, respectively. Two other comparisons were significantly different: the mean lateral pressure in the anterior annulus during extension (45%) and the

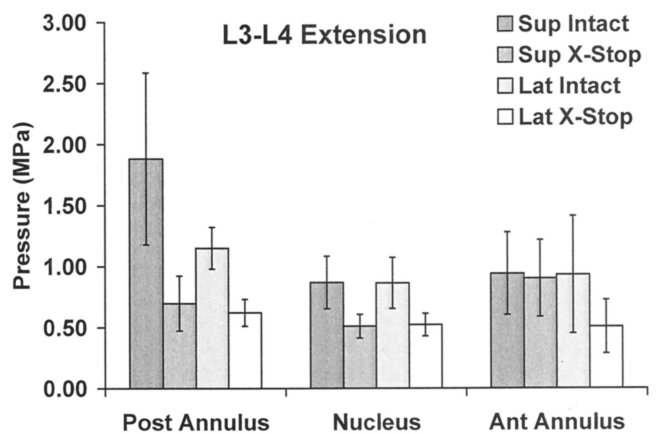


Figure 4. A bar chart of the mean pressures and standard deviations collected in the posterior annulus, nucleus, and anterior annulus of L3–L4 in extension. Pressures collected in the superior and lateral directions of specimens with and without the implant are presented. The mean superior and lateral pressures in the posterior annulus and nucleus were significantly reduced after implant placement, and the mean lateral pressure in the anterior annulus was significantly reduced.

Table 1. Mean Disc Pressures at the L3–L4 Level for the Intact and X-Stop Implanted Specimens

Position	Transducer Direction	Posterior Annulus		Nucleus		Anterior Annulus	
		Intact	X-Stop	Intact	X-Stop	Intact	X-Stop
Extension	Superior	1.88 ± 0.70 ^a	0.70 ± 0.23 ^a	0.87 ± 0.21 ^d	0.51 ± 0.10 ^d	0.94 ± 0.34	0.90 ± 0.31
Neutral	Superior	1.54 ± 0.62 ^b	0.95 ± 0.32 ^b	0.79 ± 0.17 ^e	0.63 ± 0.09 ^e	1.33 ± 0.69	1.12 ± 0.41
Flexion	Superior	1.04 ± 0.38	0.99 ± 0.25	0.84 ± 0.18 ^f	0.81 ± 0.17 ^f	1.91 ± 0.63	1.70 ± 0.55
Extension	Lateral	1.15 ± 0.17 ^c	0.62 ± 0.11 ^c	0.86 ± 0.21 ^g	0.52 ± 0.09 ^g	0.93 ± 0.48 ⁱ	0.51 ± 0.22 ⁱ
Neutral	Lateral	0.86 ± 0.18	0.75 ± 0.16	0.77 ± 0.15 ^h	0.64 ± 0.09 ^h	0.68 ± 0.32	0.56 ± 0.21
Flexion	Lateral	1.01 ± 0.34	0.90 ± 0.20	0.83 ± 0.18	0.82 ± 0.16	0.86 ± 0.29	0.86 ± 0.22

Means with common superscripts are significantly different at a *P* value of 0.05. Values are represented as mean ± standard deviation.

mean superior pressure in the nucleus during flexion (4%).

There were no significant differences between the mean pressures of the intact and implanted specimens at L2–L3 (Table 2). The only significant differences between the intact and implanted specimens at L4–L5 were between the lateral nucleus pressures in the neutral (7%) and flexed positions (9%) and the lateral anterior annulus pressures in the extended position (12%) (Table 3).

Discussion

The results of the current study suggest that the interspinous implant will not cause pressure-induced accelerated disc degeneration at levels adjacent to the implant. The most dramatic differences were observed at the level of insertion. The implant significantly decreased the intradiscal disc pressure in the posterior annulus region of the nucleus. In the extended and neutral positions, the implant appears to redirect a large portion of the load away from the intervertebral disc and to transfer that load to the spinous processes. During flexion, no appreciable change in intradiscal pressure was observed at the instrumented level, which suggests that the implant does not

alter the mechanics during flexion. In an experiment, Adams et al³ noted a paradoxical decrease in posterior annular pressure during hyperextension at the tested level. They attributed this observation to the facet joints acting as a fulcrum and redirecting most of the force from the respective disc.³ This finding is similar to the current finding, but in the case of the implant, instead of the facet joints redirecting the force, the implant acts to transfer the load from the disc to the spinous processes.

The primary focus of the current study was to understand the intradiscal pressure mechanics at the levels adjacent to the implant and how changes in pressure at these levels may lead to pressure-induced disc degeneration. The concern about degeneration at the adjacent levels was brought about by clinical^{16,30,31,39,48,63} and biomechanical^{10,12,20,26,36,44,51,57} observations in lumbar spine fusion. In the case of spinal fusion, the motion segment is entirely immobilized, and the adjacent levels are forced to flex and extend appreciably more to compensate for the lack of mobility at the fused level. A number of studies have reported radiographic findings of adjacent-level changes. Aota et al⁸ reported on 55 patients who had a stable adjacent level before lumbar fusion. After a mean 25-month follow-up period, an adjacent-level instability developed in 14 (25.5%) of the patients. Similarly, Etebar and Cahill¹⁵ reviewed the records of 125 patients and reported that adjacent-level failure developed in 18 of these patients after a mean of 45 months.

However, many of these radiographic findings do not correlate with clinical symptoms. For example, Guigui et al¹⁹ reported up to a 49% incidence of radiographic changes in 102 patients after an average follow-up period of 8.9 years. However, “no significant correlation was found between the radiographic findings and the final functional results, and only eight patients required a new surgery.”¹⁹ Similar findings have been reported by Kumar et al,^{28,29} Lehmann et al,³¹ Miyakoshi et al,³⁴ Van Horn and Bohnen,⁵² and Whitecloud et al.⁵⁸ On the other hand, there are reports of symptomatic adjacent levels that correlate very well with the radiographic findings.^{30,48} Lee³⁰ reported on 18 patients with symptomatic levels adjacent to a fusion in which 11 of the 18 patients had symptoms within 5 years. Similarly, Schlegel et al⁴⁸ reported on 58 patients treated for adjacent-

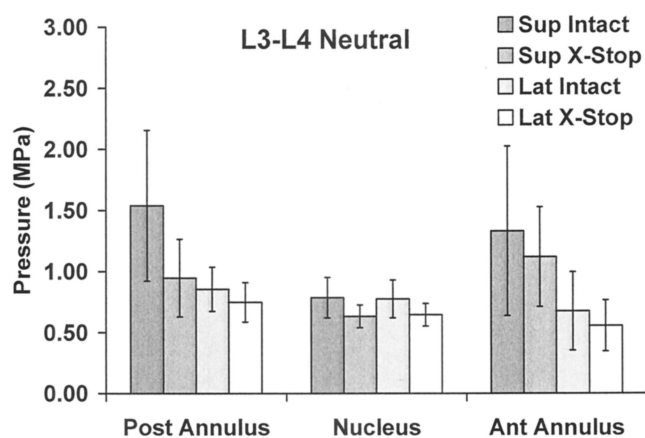


Figure 5. A bar chart of the mean pressures and standard deviations collected in the posterior annulus, nucleus, and anterior annulus of L3–L4 in the neutral position. Pressures collected in the superior and lateral directions of specimens with and without the implant are presented. The mean superior pressures in the posterior annulus and nucleus were significantly reduced after implant placement, and the mean lateral pressure in the nucleus was significantly reduced.

Table 2. Mean Disc Pressures at the L2–L3 Level for the Intact and X-Stop Implanted Specimens

Position	Transducer Direction	Posterior Annulus		Nucleus		Anterior Annulus	
		Intact	X-Stop	Intact	X-Stop	Intact	X-Stop
Extension	Superior	1.92 ± 1.55	1.47 ± 0.85	0.78 ± 0.31	0.77 ± 0.30	1.00 ± 0.61	1.10 ± 0.63
Neutral	Superior	1.18 ± 0.49	1.70 ± 1.05	0.74 ± 0.15	0.76 ± 0.18	1.43 ± 0.53	1.70 ± 0.80
Flexion	Superior	1.00 ± 0.18	1.04 ± 0.37	0.90 ± 0.23	0.89 ± 0.21	2.19 ± 1.20	2.56 ± 1.16
Extension	Lateral	1.12 ± 0.36	1.08 ± 0.28	0.78 ± 0.33	0.76 ± 0.30	0.63 ± 0.39	0.65 ± 0.36
Neutral	Lateral	0.91 ± 0.22	1.02 ± 0.31	0.72 ± 0.15	0.75 ± 0.16	0.81 ± 0.49	0.69 ± 0.19
Flexion	Lateral	1.05 ± 0.32	1.11 ± 0.45	0.89 ± 0.24	0.87 ± 0.21	1.08 ± 0.52	1.11 ± 0.46

There are no significant differences between the means of the intact and x-stop pressures at the L2–L3 level for any specimen position, anatomic location, or transducer position. Values are represented as mean ± standard deviation.

level disc disease who were asymptomatic for an average of 13.1 years. Among these patients, 36 were treated with adjacent-level fusions. Although the radiographic findings of adjacent-level degeneration are not disputed, their correlation to clinical symptoms is a matter of debate. For a better understanding of the mechanisms driving this degeneration, a number of investigators have taken a biomechanical approach.

Disc pressure studies are routinely performed to understand the changes occurring as a result of instrumentation. Chow et al¹⁰ showed that after an L4–L5 fusion, the L3–L4 intradiscal pressure increased only slightly, from 0.30 to 0.31 MPa in flexion and from 0.39 to 0.41 MPa in extension. Similarly, Rohlmann et al⁴⁴ showed that an external fixator increased the pressures above and below the fused segments only slightly. On the other hand, Cunningham et al¹² showed that the adjacent-level disc pressures increase substantially during flexion and extension, whereas the pressures at the instrumented levels decrease.

A likely reason for the differences in these biomechanical studies lies in the testing mode. Some studies were performed under load control, whereas others used displacement control. There is no conclusive evidence that one testing mode is preferential over another, but convincing arguments can be made for both modes. In an attempt to identify the differences between the two and a preference of one over the other, Dekutoski et al¹³ investigated an animal model followed up with biomechanical testing. On the basis of their findings, they concluded that displacement control appears to simulate the *in vivo* changes caused by immobilization. On the other hand,

Rohlmann et al⁴⁴ conducted a number of clinical and biomechanical pressure studies, concluding from their results that “during most daily activities, patients tend to accept the limited motion,” and that “load control is probably therefore the adequate loading condition.”

The current study was performed under load control based on the assumption that patients tend to apply a constant load instead of attempting to achieve a constant displacement. As a result of this loading modality, the magnitude of the pressures measured in the nucleus, and in anterior and posterior annulus are similar to those reported by others.^{1,4,14,32,57,61} In addition, the pressures are similar to those measured in patients by Andersson et al,^{6,7} Ortengren et al,³⁷ Sato et al,⁴⁷ Rohlmann et al,⁴⁴ and Wilke et al.⁶⁰ The pressure within the nucleus was fairly constant despite movements in flexion and extension. In addition, the pressure within the nucleus did not vary with orientation of the pressure transducer, which suggests that the pressure measured in these specimens was hydrostatic pressure. Most of the pressure changes were observed in the anterior and posterior annulus. The superior stress profiles were also more sensitive to compressive loading of the intervertebral disc than the lateral stress profiles, similar to those noted in a previous study.³²

To the authors' knowledge, there is only one study in the reported literature that addresses change in intradiscal pressure after insertion of an interspinous implant. Minns and Walsh³³ discovered that insertion of a silicone implant between two adjacent spinous processes resulted in a decrease in disc pressure. Their experiment did not include flexion–extension of the motion seg-

Table 3. Mean Disc Pressures at the L4–L5 Level for the Intact and X-Stop Implanted Specimens

Position	Transducer Direction	Posterior Annulus		Nucleus		Anterior Annulus	
		Intact	X-Stop	Intact	X-Stop	Intact	X-Stop
Extension	Superior	2.02 ± 0.72	1.65 ± 0.94	0.81 ± 0.42	0.61 ± 0.17	0.92 ± 0.30	1.07 ± 0.57
Neutral	Superior	1.40 ± 0.77	1.21 ± 0.49	0.65 ± 0.07	0.63 ± 0.07	1.35 ± 0.65	1.10 ± 0.69
Flexion	Superior	0.82 ± 0.43	0.76 ± 0.39	0.94 ± 0.37	0.90 ± 0.31	1.77 ± 0.66	1.66 ± 0.88
Extension	Lateral	1.28 ± 0.63	0.99 ± 0.24	0.80 ± 0.34	0.63 ± 0.14	0.66 ± 0.13 ^c	0.59 ± 0.13 ^c
Neutral	Lateral	0.75 ± 0.31	0.93 ± 0.41	0.69 ± 0.06 ^a	0.64 ± 0.07 ^a	0.73 ± 0.19	0.70 ± 0.19
Flexion	Lateral	0.82 ± 0.29	0.88 ± 0.38	0.87 ± 0.39 ^b	0.80 ± 0.37 ^b	1.17 ± 0.33	1.07 ± 0.20

Means with common superscripts are significantly different at *P* value of 0.05. Values are represented as mean ± standard deviation.

ments, and they did not measure disc pressures at the adjacent levels. However, the data from the current study follow the same patterns observed by Minns and Walsh,³³ and also give some insight into the pressure changes in the anterior and posterior annulus as well as adjacent levels.

It appears that the implant would not induce any degenerative changes at the adjacent levels, and that it may have some benefit for patients with pressure-related discogenic back pain, although the latter point is pure speculation. The safety and efficacy of its intended use, lumbar neurogenic claudication secondary to spinal stenosis, is currently being evaluated in a prospective randomized clinical trial.

■ Key Points

- An interspinous spacer is presented as an alternative treatment for neurogenic claudication secondary to lumbar spinal stenosis.
- The effect of the implant on disc pressure at the instrumented level and adjacent levels was evaluated.
- The implant did not affect the disc pressure at the adjacent levels and reduced the disc pressure at the instrumented level.

Acknowledgments

The authors thank the VA Rehab R&D Center, Palo Alto, CA, and St Francis Medical Technologies for their support.

References

1. Adams M, Dolan P. Is the lumbar spine loaded more heavily in sitting or standing. Hawaii: International Society for the Study of the Lumbar Spine, 1999:131.
2. Adams MA. Mechanical testing of the spine: An appraisal of methodology, results, and conclusions. *Spine* 1995;20:2151–6.
3. Adams MA, May S, Freeman BJ, et al. Effects of backward bending on lumbar intervertebral discs: Relevance to physical therapy treatments for low back pain. *Spine* 2000;25:431–7, discussion 438.
4. Adams MA, McNally DS, Dolan P. “Stress” distributions inside intervertebral discs: The effects of age and degeneration. *J Bone Joint Surg [Br]* 1996;78:965–72.
5. Amundsen T, Weber H, Lilleas F, et al. Lumbar spinal stenosis: Clinical and radiologic features. *Spine* 1995;20:1178–86.
6. Andersson GB, Ortengren R, Nachemson A. Intradiskal pressure, intraabdominal pressure, and myoelectric back muscle activity related to posture and loading. *Clin Orthop* 1977;(129):156–64.
7. Andersson GBJ, Ortengren R, Nachemson A. Quantitative studies of back loads in lifting. *Spine* 1976;1:178–85.
8. Aota Y, Kumano K, Hirabayashi S. Postfusion instability at the adjacent segments after rigid pedicle screw fixation for degenerative lumbar spinal disorders. *J Spinal Disord* 1995;8:464–73.
9. Arnoldi CC, Brodsky AE, Cauchoix J, et al. Lumbar spinal stenosis and nerve root entrapment syndromes: Definition and classification. *Clin Orthop* 1976;4–5.
10. Chow DH, Luk KD, Evans JH, et al. Effects of short anterior lumbar interbody fusion on biomechanics of neighboring unfused segments. *Spine* 1996;21:549–55.
11. Chung SS, Lee CS, Kim SH, et al. Effect of low back posture on the morphology of the spinal canal. *Skeletal Radiol* 2000;29:217–23.
12. Cunningham BW, Kotani Y, McNulty PS, et al. The effect of spinal destabilization and instrumentation on lumbar intradiscal pressure: An *in vitro* biomechanical analysis. *Spine* 1997;22:2655–63.
13. Dekutoski, MB, Schendel MJ, Ogilvie JW, et al. Comparison of *in vivo* and *in vitro* adjacent segment motion after lumbar fusion. *Spine* 1994;19:1745–51.
14. Edwards WT, Ordway NR, Zheng Y, et al. Peak stresses observed in the posterior lateral annulus. *Spine* 2001;26:1753–9.
15. Etebar S, Cahill DW. Risk factors for adjacent-segment failure following lumbar fixation with rigid instrumentation for degenerative instability. *J Neurosurg* 1999;90:163–9.
16. Frymoyer JW, Hanley EN Jr, Howe J, et al. A comparison of radiographic findings in fusion and nonfusion patients ten or more years following lumbar disc surgery. *Spine* 1979;4:435–40.
17. Fujiwara A, An HS, Lim TH, et al. Morphologic changes in the lumbar intervertebral foramen due to flexion–extension, lateral bending, and axial rotation an *in vitro* anatomic and biomechanical study. *Spine* 2001;26:876–82.
18. Giles LG. Mechanisms of neurovascular compression within the spinal and intervertebral canals. *J Manipulative Physiol Ther* 2000;23:107–11.
19. Guigui P, Lambert P, Lassale B, et al. Long-term outcome at adjacent levels of lumbar arthrodesis. *Rev Chir Orthop Reparatrice Appar Mot* 1997;83:685–96.
20. Ha KY, Schendel MJ, Lewis JL, et al. Effect of immobilization and configuration on lumbar adjacent-segment biomechanics. *J Spinal Disord* 1993;6:99–105.
21. Hawkes CH, Roberts GM. Neurogenic and vascular claudication. *J Neuro Sci* 1978;38:337–45.
22. Herno A, Airaksinen O, Saari T. Long-term results of surgical treatment of lumbar spinal stenosis. *Spine* 1993;18:1471–4.
23. Hilibrand AS, Rand N. Degenerative lumbar stenosis: Diagnosis and management. *J Am Acad Orthop Surg* 1999;7:239–49.
24. Inufusa A, An HS, Lim TH, et al. Anatomic changes of the spinal canal and intervertebral foramen associated with flexion–extension movement. *Spine* 1996;21:2412–20.
25. Katz JN, Lipson SJ, Larson MG, et al. The outcome of decompressive laminectomy for degenerative lumbar stenosis. *J Bone Joint Surg [Am]* 1991;73:809–16.
26. Kim YE, Goel VK, Weinstein JN, et al. Effect of disc degeneration at one level on the adjacent level in axial mode. *Spine* 1991;16:331–5.
27. Kirkaldy-Willis WH, Wedge JH, Yong-Hing K, et al. Pathology and pathogenesis of lumbar spondylosis and stenosis. *Spine* 1978;3:319–28.
28. Kumar MN, Baklanov A, Chopin D. Correlation between sagittal plane changes and adjacent segment degeneration following lumbar spine fusion. *Eur Spine J* 2001;10:314–9.
29. Kumar MN, Jacquot F, Hall H. Long-term follow-up of functional outcomes and radiographic changes at adjacent levels following lumbar spine fusion for degenerative disc disease. *Eur Spine J* 2001;10:309–13.
30. Lee CK. Accelerated degeneration of the segment adjacent to a lumbar fusion. *Spine* 1988;13:375–7.
31. Lehmann TR, Spratt KF, Tozzi JE, et al. Long-term follow-up of lower lumbar fusion patients. *Spine* 1987;12:97–104.
32. McNally DS, Adams MA. Internal intervertebral disc mechanics as revealed by stress profilometry. *Spine* 1992;17:66–73.
33. Minns RJ, Walsh WK. Preliminary design and experimental studies of a novel soft implant. *Spine* 1997;22:1819–25, discussion 1826–7.
34. Miyakoshi N, Abe E, Shimada Y, et al. Outcome of one-level posterior lumbar interbody fusion for spondylolisthesis and postoperative intervertebral disc degeneration adjacent to the fusion. *Spine* 2000;25:1837–42.
35. Nachemson AL. Disc pressure measurements. *Spine* 1981;6:93–7.
36. Nagata H, Schendel MJ, Transfeldt EE, et al. The effects of immobilization of long segments of the spine on the adjacent and distal facet force and lumbosacral motion. *Spine* 1993;18:2471–9.
37. Ortengren R, Andersson GB, Nachemson AL. Studies of relationships between lumbar disc pressure, myoelectric back muscle activity, and intraabdominal (intra-gastric) pressure. *Spine* 1981;6:98–103.
38. Panjabi MM, Takata K, Goel VK. Kinematics of lumbar intervertebral foramen. *Spine* 1983;8:348–57.
39. Penta M, Sandhu A, Fraser RD. Magnetic resonance imaging assessment of disc degeneration 10 years after anterior lumbar interbody fusion. *Spine* 1995;20:743–7.
40. Porter RW. Spinal stenosis and neurogenic claudication. *Spine* 1996;21:2046–52.
41. Rauschnig W. Normal and pathologic anatomy of the lumbar root canals. *Spine* 1987;12:1008–19.
42. Reeg SE. A review of comorbidities and spinal surgery. *Clin Orthop* 2001;(384):101–9.
43. Rohlmann A, Calisse J, Bergmann G, et al. Internal spinal fixator stiffness has only a minor influence on stresses in the adjacent discs. *Spine* 1999;24:1192–5.
44. Rohlmann A, Neller S, Bergmann G, et al. Effect of an internal fixator and a

- bone graft on intersegmental spinal motion and intradiscal pressure in the adjacent regions. *Eur Spine J* 2001;10:301–8.
45. Rothman SL. Dynamic effect on the lumbar spinal canal. *Spine* 1998;23:1506–7.
 46. Salibi BS. Neurogenic intermittent claudication and stenosis of the lumbar spinal canal. *Surg Neurol* 1976;5:269–72.
 47. Sato K, Kikuchi S, Yonezawa T. *In vivo* intradiscal pressure measurement in healthy individuals and in patients with ongoing back problems. *Spine* 1999;24:2468–74.
 48. Schlegel JD, Smith JA, Schlessener RL. Lumbar motion segment pathology adjacent to thoracolumbar, lumbar, and lumbosacral fusions. *Spine* 1996;21:970–81.
 49. Schmid MR, Stucki G, Duetz S, et al. Changes in cross-sectional measurements of the spinal canal and intervertebral foramina as a function of body position: *In vivo* studies on an open-configuration MR system. *AJR Am J Roentgenol* 1999;172:1095–102.
 50. Schonstrom N, Lindahl S, Willen J, et al. Dynamic changes in the dimensions of the lumbar spinal canal: An experimental study *in vitro*. *J Orthop Res* 1989;7:115–21.
 51. Shono Y, Kaneda K, Abumi K, et al. Stability of posterior spinal instrumentation and its effects on adjacent motion segments in the lumbosacral spine. *Spine* 1998;23:1550–8.
 52. Van Horn JR, Bohnen LM. The development of discopathy in lumbar discs adjacent to a lumbar anterior interbody spondylodesis: A retrospective matched-pair study with a postoperative follow-up of 16 years. *Acta Orthop Belg* 1992;58:280–6.
 53. Verbiest H. Neurogenic intermittent claudication in cases with absolute and relative stenosis of the lumbar vertebral canal (ASLC and RSLC), in cases with narrow lumbar intervertebral foramina, and in cases with both entities. *Clin Neurosurg* 1973;20:204–14.
 54. Verbiest H. Stenosis of the lumbar vertebral canal and sciatica. *Neurosurg Rev* 1980;3:75–89.
 55. Verbiest H. The treatment of lumbar spondyloptosis or impending lumbar spondyloptosis accompanied by neurologic deficit and/or neurogenic intermittent claudication. *Spine* 1979;4:68–77.
 56. Vitzthum HE, König A, Seifert V. Dynamic examination of the lumbar spine by using vertical, open magnetic resonance imaging. *J Neurosurg* 2000;93:58–64.
 57. Weinhoffer SL, Guyer RD, Herbert M, et al. Intradiscal pressure measurements above an instrumented fusion: A cadaveric study. *Spine* 1995;20:526–31.
 58. Whitecloud TS III, Davis JM, Olive PM. Operative treatment of the degenerated segment adjacent to a lumbar fusion. *Spine* 1994;19:531–6.
 59. Wildermuth S, Zanetti M, Duetz S, et al. Lumbar spine: Quantitative and qualitative assessment of positional (upright flexion and extension) MR imaging and myelography. *Radiology* 1998;207:391–8.
 60. Wilke HJ, Neef P, Caimi M, et al. New *in vivo* measurements of pressures in the intervertebral disc in daily life. *Spine* 1999;24:755–62.
 61. Wilke HJ, Wolf S, Claes LE, et al. Influence of varying muscle forces on lumbar intradiscal pressure: An *in vitro* study. *J Biomech* 1996;29:549–55.
 62. Willen J, Danielson B, Gaultz A, et al. Dynamic effects on the lumbar spinal canal: Axially loaded CT myelography and MRI in patients with sciatica and/or neurogenic claudication. *Spine* 1997;22:2968–76.
 63. Wimmer C, Gluch H, Krismer M, et al. AP translation in the proximal disc adjacent to lumbar spine fusion: A retrospective comparison of mono- and polysegmental fusion in 120 patients. *Acta Orthop Scand* 1997;68:269–72.